

Fulminant Liver Failure After Radical Prostatectomy in the Hyperlordotic Position

Avery Tung, MD

Steven Roth, MD

Michael F. O'Connor, MD

Wenhua Liu, MD, PhD

John E. Ellis, MD

In the hyperlordotic position, the patient's hips are above the feet and head. This position has previously been associated with partial vena caval occlusion, increased venous pressures, and spinal cord infarction. We describe a case of fulminant hepatic failure after radical retropubic prostatectomy performed in the hyperlordotic position.

(Anesth Analg 2006;103:986-8)

In the hyperlordotic position, the operating room table is flexed into a convex position and the patient's hips are positioned above the feet and head (Fig. 1). Used to facilitate abdominal surgery, this position can also cause rotation of the liver, partial occlusion of the inferior vena cava, and subsequent increases in venous pressure (1,2). Although the hyperlordotic position has been associated with spinal cord infarction (3,4), paravertebral muscle rhabdomyolysis (5), and paraplegia (6), liver injury resulting from this position has not been reported, either in the literature or to the American Society of Anesthesiologists Closed Claims Database (personal communication, K. L. Posner, PhD, University of Washington, 5/24/05). We report a case of fulminant hepatic failure after radical retropubic prostatectomy performed in the hyperlordotic position.

CASE REPORT

The patient was an otherwise healthy 62-yr-old with no significant medical history. He had had an "executive physical" a year before with no abnormal findings, and his exercise tolerance was normal. He had no allergies and had previously undergone both general and epidural anesthesia without complication. His preoperative arterial blood pressure was 127/84, heart rate (HR) was 77 bpm, and hematocrit (Hct) was 44%. No preoperative liver function tests were ordered.

From the Department of Anesthesia and Critical Care and Pathology, University of Chicago, Chicago Illinois.

Accepted for publication May 30, 2006.

Supported entirely by the Department of Anesthesia and Critical Care. The authors have no commercial interest in the subject matter of this report.

Address correspondence and reprint requests to Avery Tung, M.D., Associate Professor, Department of Anesthesia and Critical Care, University of Chicago, 5841 S. Maryland Ave, MC4028, Chicago, IL 60637. Address e-mail to atung@dacc.uchicago.edu.

Copyright © 2006 International Anesthesia Research Society
DOI: 10.1213/01.ane.0000232441.58623.40

On the day of surgery, a lumbar epidural catheter was placed and 20 mL of 2% lidocaine given in divided doses to produce a T10 sensory blockade. The patient was placed in the hyperlordotic position per surgeon request. Because of positioning-related discomfort, general anesthesia was induced with IV propofol and maintained with 2%–3% end-tidal desflurane via endotracheal tube.

Over the next 3 h, his mean arterial pressures (MAP) ranged from 50–55 mm Hg, the HR was 70 bpm, he breathed spontaneously with end-tidal CO₂ levels 32 to 46 mm Hg, and his bispectral index (BIS) values were 45 to 62. The epidural catheter was redosed periodically with 5 mL 2% lidocaine. Autologous red blood cells (RBC) 1 U and 1000 mL 5% albumin were given to treat MAP ≤50 mm Hg. Because of surgical constraints, urine output was not measured.

Twenty minutes before emergence, the patient was returned to the unflexed position. HR increased to 90 bpm and ST-T wave abnormalities in electrocardiogram (ECG) lead II were observed. Bolus doses of IV esmolol (100 mg) and metoprolol (5 mg) were given to treat these changes. After skin closure, the patient was then tracheally extubated and transported to the recovery room awake and conversant with a MAP of 105/60 and HR 80 bpm. He had no chest pain. A venous blood sample revealed pH = 7.19, Pco₂ = 48 mm Hg, base deficit = -9.5 meq/L, and Hct = 30.3%. The surgically straightforward case lasted 5 h and 15 min, estimated blood loss was 1100 mL, and fluid administration totaled 5100 mL.

Because of continued ECG abnormalities and the patient's complaints of abdominal pain in the recovery room, 5 mg morphine and 10 mg metoprolol were given IV in divided doses. Lactated Ringer's solution was infused at 140 mL/h, and urine output during the first hour was 120 mL. A transthoracic echocardiogram revealed a hyperdynamic left ventricle, normal right ventricle and volume status, and no regional wall motion abnormalities. A repeat arterial blood gas showed: pH = 7.24, Pco₂ = 44, and Po₂ = 56 with base deficit = -7.8 meq/L and lactate = 5.6 mg/dL. 1000 mL 5% albumin and 500 mL packed red blood cells were given for a central venous pressure of 3 mm Hg. Laboratory values at this time were: creatine kinase (CK) = 242 U/L, serum glutamic oxaloacetic transaminase (SGOT) = 3519 U/L, serum glutamic pyruvic transaminase (SGPT) = 4774 U/L, lipase = 2772 U/L, amylase = 621 U/L, ammonia = 178 mg/dL, Hct = 26.7%, and International Normalized Ratio = 4.27. Tests for hepatitis B and C were negative. The

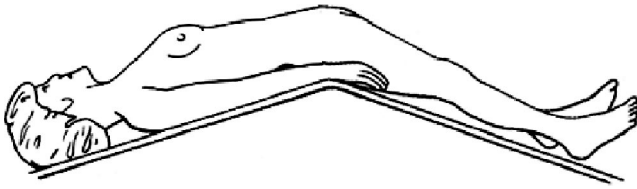

Figure 1. Hyperlordotic position.

patient was transferred to the intensive care unit for further observation.

He was endotracheally reintubated on postoperative day 1 for progressive hypoxemic respiratory failure, shock unresponsive to multiple vasoactive drugs, and anuria. Liver function tests remained abnormal: lipase 3066 U/L, amylase 813 U/L, CK 5060 U/L, SGOT = 9470 U/L, SGPT = 6130 U/L, and lactate dehydrogenase = 8710 U/L. His fibrin level = 61 mg/dL (normal 226–463 mg/dL) and plasminogen level = 27% (normal 81%–172%), suggesting disseminated intravascular coagulation (DIC). Flexible sigmoidoscopy revealed a dusky, ischemic colon. The patient's circulatory failure worsened and he became asystolic on postoperative day 3. Cardiopulmonary resuscitation was unsuccessful.

On autopsy, the liver showed extensive hemorrhagic and focal centrilobular necrosis (Fig. 2). No cirrhosis, eosinophilia, or portal tract inflammation was noted. The heart, brain, kidneys, and liver were free of vascular disease, anatomic abnormalities, or thromboemboli. Hemorrhagic necrosis was seen in the entire small intestine from the pylorus to the colon. The cause of death was judged to be hepatic failure resulting from ischemia.

DISCUSSION

Acute perioperative liver failure is usually associated with severe preexisting liver dysfunction (7). Our patient, however, developed fatal postoperative liver failure despite having no symptomatic preoperative hepatic disease. Moreover, postmortem liver examination effectively excluded preoperative cirrhosis or infectious hepatitis. The lack of eosinophilia on liver histology and immediate postoperative presentation also made desflurane toxicity unlikely (8). The finding of focal centrilobular necrosis was most consistent with ischemic injury

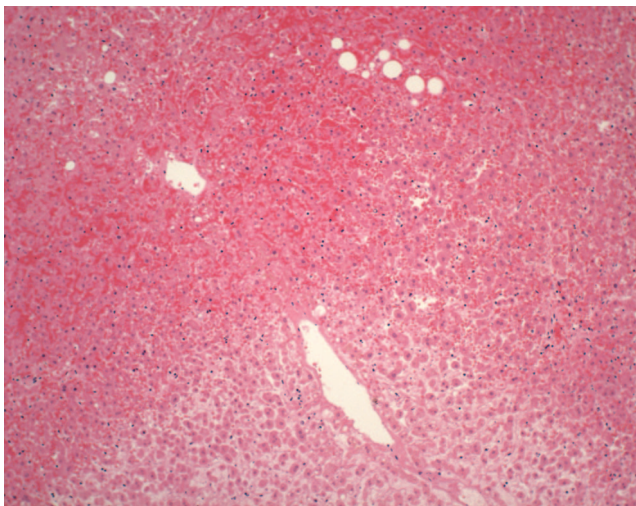


Figure 2. Microscopic examination of liver histology showing infarcted liver with centrilobular necrosis (Hematoxylin & eosin stain, 10 \times).

and strongly suggested an acute perioperative ischemic process.

One possible factor may have been the intraoperative use of the hyperlordotic position. In normal subjects, this position rotates the liver, obstructing blood flow through the inferior vena cava at the level of the diaphragm, increasing inferior vena caval pressure, and decreasing right atrial pressures (1,2). Transmittance of increased vena caval pressure to epidural veins has been postulated to reduce spinal cord blood flow and predispose to spinal cord infarction (3). We hypothesize that hyperlordosis predisposed our patient to inadequate hepatic blood flow by compressing the liver capsule, kinking the hepatic artery, or increasing inferior vena caval pressures and reducing the pressure gradient for hepatic blood flow. Both increases in venous pressure (9) and liver compression (10) have been associated with reduced liver blood flow. In our case, position-related obstruction to superior mesenteric or hepatic arterial flow was more likely, as neither liver capsule compression nor increases in venous pressures with right heart failure explained the intestinal ischemia we observed. When combined with mild hypotension, this positional change in blood supply to the liver and intestine produced the signs and symptoms we observed.

In our case, the MAP was between 50–55 mm Hg intraoperatively for 90–120 minutes. This approach has been advocated as a strategy to safely reduce blood loss during prostatectomy (11). Studies examining the relationship between hypotension and ischemic hepatitis (12) or adequacy of splanchnic perfusion (11), however, suggest that this factor alone was unlikely to have caused the severe liver and intestinal injury seen in our patient. Moreover, our patient was awake, alert, and had no focal postoperative neurologic findings, indicating that intraoperative MAP had been sufficient to sustain brain and spinal cord function.

Other factors may also have contributed to liver failure in our patient. Direct compression of abdominal contents during surgical retraction may have worsened liver or gut blood flow. No evidence of intestinal trauma on autopsy, however, supported this possibility. Epidural anesthesia may have reduced gut blood flow and masked clinical signs of gut ischemia. In several series of epidural anesthesia and deliberate hypotension, however, liver failure was not seen (13,14). Although prostatectomy itself may cause DIC (15), vascular occlusion, and subsequent liver failure, the lack of microthrombi on autopsy excluded that possibility. Overall, we believe it unlikely that hypotension, retractor pressure, epidural anesthesia, or DIC alone adequately explained the severity of liver and intestinal ischemia we observed. The ECG changes associated with return to a normal position further support a transient, positioning-related alteration in blood flow to the liver and intestines.

In summary, we report a case of fulminant, fatal hepatic failure after radical retropubic prostatectomy in the hyperlordotic position. In our case, the absence

of any other clearly causative factor for liver damage suggests an effect of hyperlordosis on mesenteric and hepatic artery blood flow, resulting in severe liver and intestinal ischemia. We recommend that the position be avoided if possible. If intraoperative hyperlordosis is necessary, normotension should be maintained, the duration be as short as possible, and liver viability (including measurements of lactate and acid-base balance) be monitored closely.

REFERENCES

1. Brigden W, Howarth S, Sharpey-Schafer EP. Postural changes in the peripheral blood flow of normal subjects with observations on vaso-vagal fainting reactions as a result of tilting, the lordotic posture, pregnancy, and spinal anaesthesia. *Clin Sci* 1950; 9:79-90.
2. Bull GM. Postural Proteinuria. *Clin Sci* 1949;7:77-108.
3. Amoiridis G, Wohrle JC, Langkafel M, et al. Spinal cord infarction after surgery in a patient in the hyperlordotic position. *Anesthesiology* 1996;84:228-30.
4. Beloeil H, Albaladejo P, Hoen S, et al. Bilateral lower limb hypoesthesia after radical prostatectomy in the hyperlordotic position under general anesthesia. *Can J Anaesth* 2003;50:653-6.
5. Uratsuji Y, Ijichi K, Irie J, et al. Rhabdomyolysis after abdominal surgery in the hyperlordotic position enforced by pneumatic support. *Anesthesiology* 1999;91:310-2.
6. Bromage PR. Spinal thrombophlebitis after hypotensive anesthesia. *N Z Med J* 1974;519-21.
7. Wiklund RA. Preoperative preparation of patients with advanced liver disease. *Crit Care Med* 2004;32:S106-15.
8. Tung D, Yoshida EM, Wang CS, Steinbrecher UP. Severe desflurane hepatotoxicity after colon surgery in an elderly patient. *Can J Anaesth* 2005;52:133-6.
9. Caldwell CB, Ricotta JJ. Changes in visceral blood flow with elevated intraabdominal pressure. *J Surg Res* 1987;43:14-20.
10. Jona JZ, Goldstein IR. Compression hepatic necrosis in a child. *J Trauma* 1977;17:402-4.
11. Suttner SW, Boldt J, Schmidt CC, et al. The effects of sodium nitroprusside-induced hypotension on splanchnic perfusion and hepatocellular integrity. *Anesth Analg* 1999;89:1371-7.
12. Seeto RK, Fenn B, Rockey DC. Ischemic hepatitis: clinical presentation and pathogenesis. *Am J Med* 2000;109:109-13.
13. Sharrock NE, Mineo R, Urquhart B. Haemodynamic effects and outcome analysis of hypotensive extradural anaesthesia in controlled hypertensive patients undergoing total hip arthroplasty. *Br J Anaesth* 1991;67:17-25.
14. Williams-Russo P, Sharrock NE, Mattis S, et al. Randomized trial of hypotensive epidural anesthesia in older adults. *Anesthesiology* 1999;91:926-35.
15. Deutsch E. Disseminated intravascular coagulation in prostatic disease. *Prog Clin Biol Res* 1976;6:313-27.